

# EAU GUIDELINES ON PAEDIATRIC UROLOGY

*(Limited text update April 2024)*

C. Radmayr (Chair), G. Bogaert (Vice-chair), A. Bujons, B. Burgu, M.S. Castagnetti, F. O'Kelly, N.A Pakkasjärvi, J. Quaedackers, Y.F.H. Rawashdeh, M.S. Silay, L.A 't Hoen

Guidelines Associates: U.K. Kennedy, M. Gnech, M. Skott, A. van Uitert, A. Zachou

Guidelines Office: C. Bezuidenhout

## Introduction

Due to the scope of the extended Guidelines on Paediatric Urology, only a short introduction of the individual chapter in combination with recommendations can be given in this pocket version. Additionally, some algorithms and flow charts are enclosed. For further details please refer to the full length version.

## PHIMOSIS

Phimosis is either primary (physiological), with no sign of scarring, or secondary (pathological), resulting from scarring due to conditions such as balanitis xerotica obliterans.

Childhood circumcision should not be recommended without a medical reason. An absolute indication for circumcision is secondary phimosis. Contraindications are congenital anomalies of the penis, particularly hypospadias or buried penis, as the foreskin may be required for a reconstructive procedure.

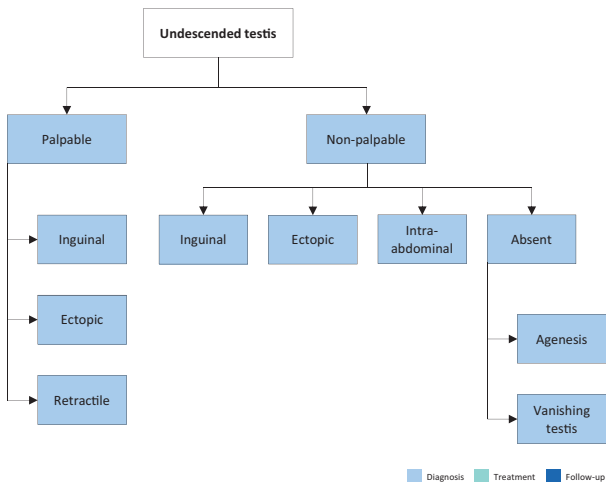
Paraphimosis is characterised by retracted foreskin with the constrictive ring localised at the level of the sulcus.

<b>Recommendations</b>	<b>Strength rating</b>
Offer topical corticosteroids (ointment or cream) as first-line treatment in symptomatic phimosis.	Strong
Consider surgical intervention if patient / caregivers prefer for symptomatic phimosis.	Strong
Offer circumcision in case of balanitis xerotica obliterans (BXO) or phimosis refractory to treatment.	Strong
Offer treatment for asymptomatic phimosis in infants with a risk of recurrent urinary tract infection due to upper urinary tract abnormalities (vesico-ureteral reflux or posterior urethral valves).	Strong
Inform patients about the risk of meatal stenosis in BXO.	Strong
Await spontaneous resolution of asymptomatic preputial adhesions before puberty.	Weak
Treat paraphimosis by manual reposition and proceed to surgery if this fails.	Strong
Do not perform simple circumcision if phimosis is associated with other penile anomalies such as buried penis, congenital penile curvature, epispadias or hypospadias.	Strong

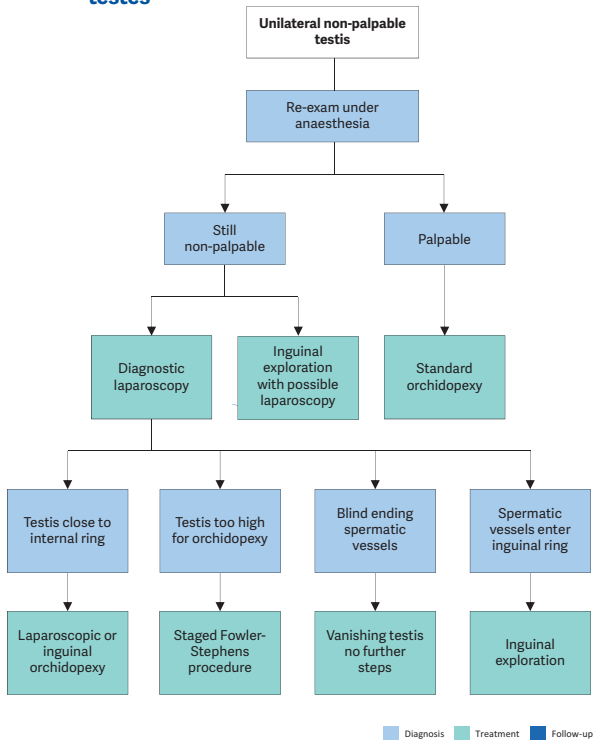
## UNDESCENDED TESTIS

Cryptorchidism or undescended testis is one of the most common congenital malformations of male neonates with an incidence of 1.0-4.6% of full-term neonates. Boys with one undescended testis have a lower fertility rate whereas boys with bilateral undescended testes suffer both, lower fertility and paternity rates. In addition, boys who are treated for an undescended testis have an increased risk of developing testicular malignancy. Therefore, screening and self-examination both during and after puberty is recommended.

**Figure 1: Classification of undescended testes**



**Figure 2: Treatment of unilateral non-palpable undescended testes**



Recommendations	Strength rating
Do not offer medical or surgical treatment for retractile testes instead undertake close follow-up on a yearly basis until puberty.	Strong
Perform surgical orchidolysis and orchidopexy before the age of twelve months, and by eighteen months at the latest.	Strong
Evaluate male neonates with bilateral non-palpable testes for possible disorders of sex development.	Strong
Perform a diagnostic laparoscopy to locate an intra-abdominal testicle.	Strong
Hormonal therapy in unilateral undescended testes is of no benefit for future paternity.	Strong
Offer endocrine treatment in case of bilateral undescended testes.	Weak
Inform the patient/caregivers about the increased risk of a later malignancy with an undescended testis in a post-pubertal boy or older and discuss removal in case of a contralateral normal testis in a scrotal position.	Weak

## TESTICULAR TUMOURS IN PREPUBERTAL BOYS

Testicular tumours account for approximately 1-2% of all paediatric solid tumours. In prepubertal boys most intratesticular tumours are benign and teratomas and yolk sac tumours more common than germ cell tumours, whereas post-puberty the tumours are most likely malignant.

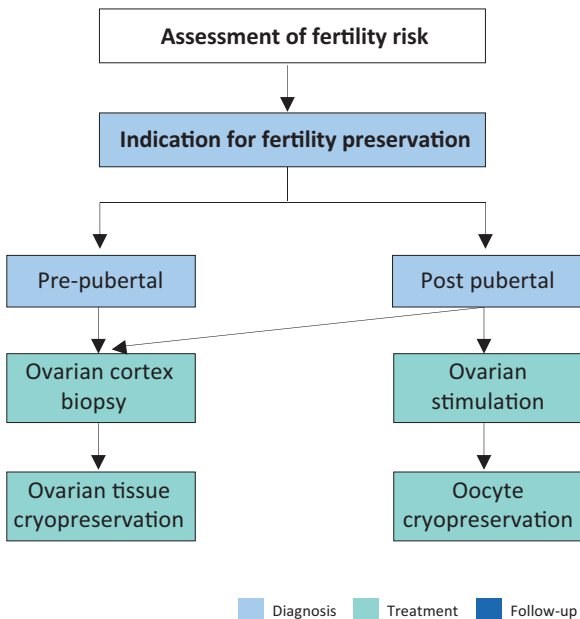
<b>Recommendations</b>	<b>Strength rating</b>
High-resolution ultrasound (7.5 – 12.5 MHz), preferably a doppler ultrasound, should be performed to confirm the diagnosis.	Strong
Alpha-fetoprotein should be determined in prepubertal boys with a testicular tumour before surgery.	Strong
Surgical exploration should be done with the option for frozen section, but not as an emergency operation.	Strong
Organ-preserving surgery should be performed in all benign tumours.	Strong
Staging (magnetic resonance imaging abdomen/computed tomography chest) should only be performed in patients with a malignant tumour to exclude metastases.	Strong
Magnetic resonance imaging should only be performed in patients with the potential malignant Leydig or Sertoli-cell-tumours to rule out lymph node enlargement.	Weak
Patients with a non-organ confined tumour should be referred to paediatric oncologists post-operatively.	Weak

## **FERTILITY PRESERVATION IN CHILDREN AND ADOLESCENTS**

The continuous increase in the incidence of paediatric cancers and post-treatment survivorship over the years coupled with the further development of potentially gonadotoxic therapies, has contributed to the recognition and rapid endorsement of fertility preservation counselling for prepubertal children and adolescents. Patients and caregivers should be informed not only about the impact of gonadotoxic treatments on future fertility but also about

fertility-preservation options and their risk-benefit ratio. There are also a number of non-oncological congenital anomalies where fertility preservation can become an issue.

**Figure 3: Ovarian tissue cryopreservation for girls and adolescents:**



*Adapted from Anderson et al. 2015.*

<b>Recommendations</b>	<b>Strength rating</b>
Inform patients and caregivers about the impact of gonadotoxic treatments on future fertility and about fertility preservation options and their risk-benefit balance.	Strong
Discuss the indications and options for fertility preservation in a paediatric multidisciplinary fertility preservation team and consider the toxicity of the planned therapy, the age and pubertal status as well ethical and financial issues.	Strong

## HYDROCELE

A communicating hydrocele vacillates in size, usually relative to activity. It is diagnosed by medical history and physical investigation, the swelling is translucent, and transillumination of the scrotum confirms the diagnosis. Non-communicating hydroceles are found secondary to minor trauma, testicular torsion, epididymitis, or varicocele operation, or may appear as a recurrence after primary repair of a communicating hydrocele.

<b>Recommendations</b>	<b>Strength rating</b>
Observe hydrocele for twelve months prior to considering surgical treatment.	Strong
Perform early surgery if there is suspicion of a concomitant inguinal hernia or underlying testicular pathology.	Strong
Perform ultrasound in case of doubt about the character of an intrascrotal mass, or suspicion of an abdominoscrotal hydrocele.	Strong



Close the processus vaginalis at the inguinal ring.	Strong
Do not use sclerosing agents in children with hydroceles, because of the risk for chemical peritonitis.	Strong

## ACUTE SCROTUM

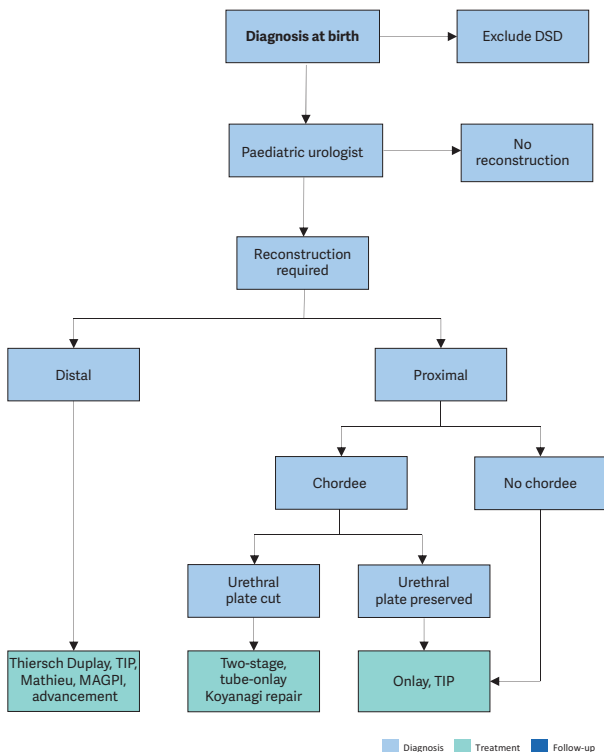
Acute scrotum is a paediatric urological emergency, most commonly caused by torsion of the testis or appendix testis, or epididymitis/epididymo-orchitis.

## HYPOSPADIAS

Hypospadias are usually classified according to the anatomical location of the proximally displaced urethral orifice.

Patients with hypospadias should be diagnosed at birth. The diagnostic evaluation also includes an assessment of associated anomalies, which include cryptorchidism and open processus vaginalis or inguinal hernia. Severe hypospadias with unilaterally or bilaterally impalpable testis, or with ambiguous genitalia, require a complete genetic and endocrine work-up immediately after birth to exclude disorders of sex development, especially congenital adrenal hyperplasia.

**Figure 4: Algorithm for the management of hypospadias**



*DSD = disorders of sex development; TIP = tubularised incised plate urethroplasty; MAGPI = meatal advancement and glanuloplasty incorporated.*

Recommendations	Strength rating
At birth, differentiate isolated hypospadias from disorders of sex development which are mostly associated with cryptorchidism or micropenis.	Strong
Counsel caregivers on functional indications for surgery, aesthetically feasible operative procedures (psychological, cosmetic indications) and possible complications.	Strong
In children diagnosed with proximal hypospadias and a small appearing penis, reduced glans circumference or reduced urethral plate, pre-operative hormonal androgen stimulation treatment is an option but the body of evidence to accentuate its harms and benefits is inadequate.	Weak
For distal hypospadias, offer Duplay-Thiersch urethroplasty, original and modified tubularised incised plate urethroplasty; use the onlay urethroplasty or two-stage procedures in more severe hypospadias. A treatment algorithm is presented (Figure 4). Correct significant ( $> 30^\circ$ ) curvature of the penis.	Weak
Ensure long-term follow-up to detect urethral stricture, voiding dysfunctions and recurrent penile curvature, ejaculation disorder, and to evaluate patient's satisfaction.	Strong
Use validated objective scoring systems to assist in evaluating the functional and cosmetic outcome.	Strong

## CONGENITAL PENILE CURVATURE

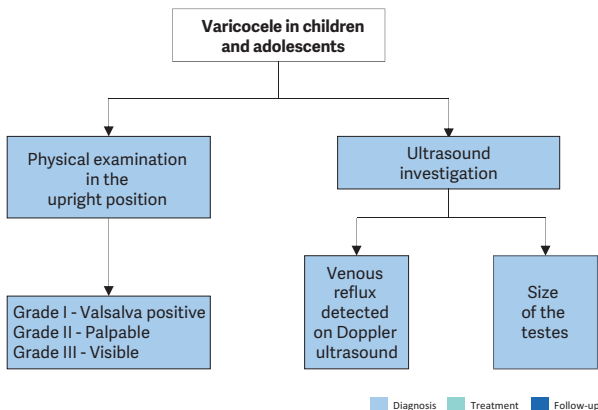
Congenital penile curvature presents penile bending of a normally formed penis due to corporal disproportion. Most of the cases are ventral deviations. Curvature  $> 30^\circ$  is considered clinically significant; curvature  $> 60^\circ$  may interfere with satisfactory sexual intercourse in adulthood. The treatment is surgical.

Recommendations	Strength rating
Ensure that a thorough medical history is taken and a full clinical examination done to rule out associated anomalies in boys presenting with congenital curvature.	Strong
Provide photo documentation of the erect penis from different angles as a prerequisite in the pre-operative evaluation.	Strong
Perform surgery after weighing aesthetic as well as functional implications of the curvature.	Weak
At the beginning as well as at the end of surgery, perform artificial erection tests.	Strong

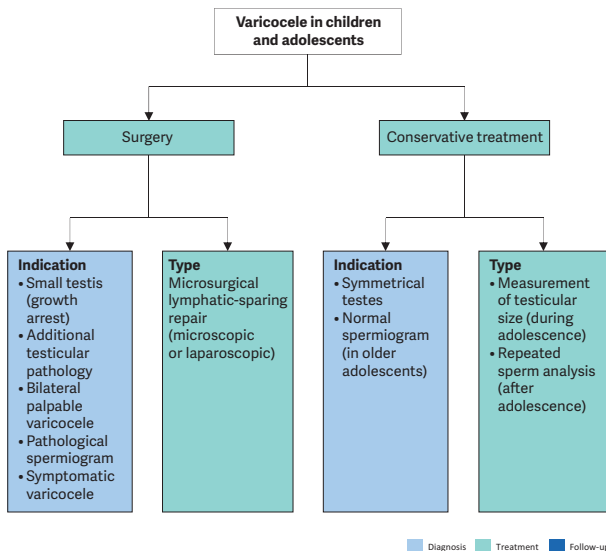
## VARICOCELE IN CHILDREN AND ADOLESCENTS

Varicocele is unusual in boys under ten years of age, but becomes more frequent at the beginning of puberty. Fertility problems will arise in about 20% of adolescents with varicocele. Testicular catch-up growth and improvement in sperm parameters after varicocelectomy have been reported in adolescents. Varicocele is mostly asymptomatic, rarely causing pain at this age. Diagnosis and classification depend upon the clinical finding and US investigation.

**Figure 5: Algorithm for the diagnosis of varicocele in children and adolescents**



**Figure 6: Algorithm for the management of varicocele in children and adolescents**

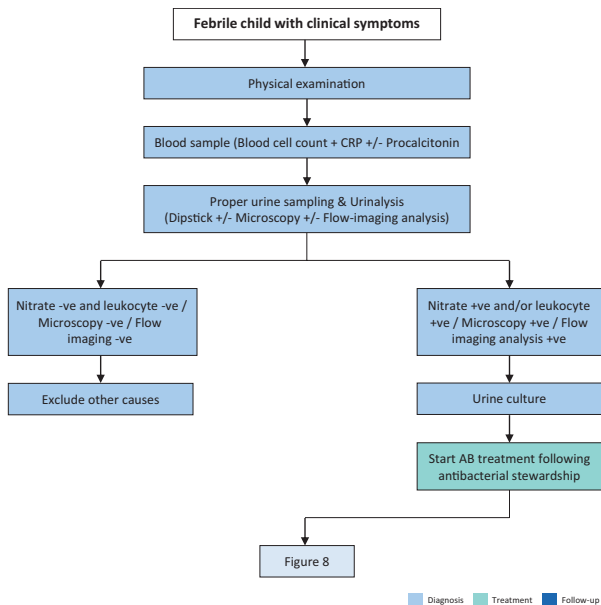


Recommendations	Strength rating
Examine varicocele in the standing position and classify into three grades.	Strong
Use scrotal ultrasound to evaluate testicular volume and to detect venous reflux in the supine and upright position and during Valsalva manoeuvre.	Strong

In all pre-pubertal boys with a varicocele and in all isolated right varicoceles perform standard abdominal ultrasound to rule out a retroperitoneal mass.	Strong
Inform caregivers and patients and offer surgery for varicocele associated with a persistent small testis (size difference of > 2 mL or 20%).	Strong
<p>Varicocele treatment can be also considered under the following circumstances:</p> <ul style="list-style-type: none"> <li>• symptomatic varicocele;</li> <li>• additional testicular condition affecting fertility such as a contralateral testicular condition;</li> <li>• bilateral palpable varicocele;</li> <li>• pathological sperm quality (in older adolescents);</li> <li>• cosmetic reasons related to their scrotal swelling.</li> </ul>	Weak
Use some form of optical magnification (microscopic or laparoscopic magnification) for surgical ligation.	Strong
Use lymphatic-sparing varicocelectomy to prevent hydrocele formation.	Strong

## URINARY TRACT INFECTIONS IN CHILDREN

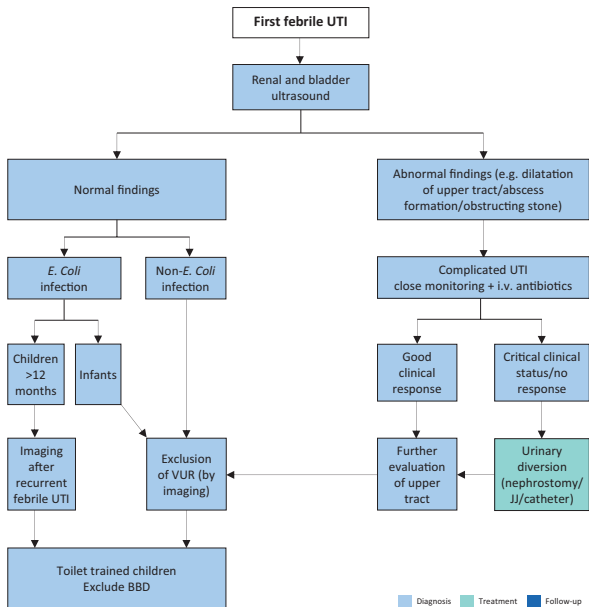
Figure 7: Algorithm for the management of a first febrile UTI



CRP = C-reactive protein; AB = antibiotic



**Figure 8: Diagnosis strategy for first febrile UTI**



*BBD = bladder and bowel dysfunction; VUR = vesicoureteral reflux; i.v. = intravenous; UTI = urinary tract infection*

Recommendations	Strength rating
Take a medical history, assess clinical signs and symptoms and perform a physical examination to diagnose children suspected of having a urinary tract infection (UTI).	Strong

Exclude bladder- and bowel dysfunction in any toilet-trained child with febrile and/or recurrent UTI.	Strong
Clean catch urine can be used for screening for UTI. Bladder catheterisation and suprapubic bladder aspiration to collect urine can be used for urine cultures.	Strong
Do not use plastic bags for urine sampling in non-toilet-trained children since it has a high risk of false-positive results.	Strong
Midstream urine is an acceptable technique for toilet-trained children.	Strong
The choice between oral and parenteral therapy should be based on patient age; clinical suspicion of urosepsis; illness severity; refusal of fluids, food and/or oral medication; vomiting; diarrhoea; non-compliance; complicated pyelonephritis.	Strong
Treat febrile UTIs with four to seven day courses of oral or parenteral therapy.	Strong
Treat complicated febrile UTI with broad-spectrum antibiotics.	Strong
Offer long-term antibacterial prophylaxis in case of high susceptibility to UTI and risk of acquired renal damage and lower urinary tract symptoms.	Strong
In selected cases consider dietary supplements as an alternative or add-on preventive measure.	Strong
In infants with febrile UTI use renal and bladder ultrasound to exclude obstruction of the upper and lower urinary tract within 24 hours.	Strong

In infants, exclude vesicoureteral reflux after first episode of febrile UTI with a non- <i>E. Coli</i> infection. In children more than one year of age with an <i>E. Coli</i> infection, exclude vesicoureteric reflux after the second febrile UTI.	Strong
--	--------

## DAY-TIME LOWER URINARY TRACT DYSFUNCTION

Urinary incontinence in children may be caused by congenital or neurologic abnormalities, however, many children have functional bladder problems for which the term day-time lower urinary tract (LUT) conditions is used. Day-time LUTD has a high prevalence ranging between 1%-20%. Symptoms can be classified as filling-phase (storage) dysfunctions and voiding-phase (emptying) dysfunctions.

**Table 1: Management algorithm**

<b>Children above 5 years of age applying with LUTS</b>
<b>DIAGNOSTIC WORK-UP</b>
Voiding diary 2-3 full days minimum
Bristol Stool scale
Physical exam <ul style="list-style-type: none"> <li>- To exclude neurogenic pathology or anatomic problems (meatal stenosis, labial fusion)</li> </ul>
Urinalysis <ul style="list-style-type: none"> <li>- To exclude presence of UTO or any other pathology (DM, DI)</li> </ul>
Uroflowmetry and PVR determination (USG or bladder scan) <ul style="list-style-type: none"> <li>- To evaluate urine flow and emptying efficacy</li> </ul>
Questionnaires (optional) <ul style="list-style-type: none"> <li>- To evaluate voiding and bowel habits, wetting severity/frequency, fluid intake, quality of life</li> </ul>

<p>Ultrasonography (optional)</p> <ul style="list-style-type: none"> <li>- To determine bladder wall thickness, upper tract changes, signs of constipation</li> </ul>
<p>Urodynamic studies (not required unless refractory to management)</p>
<p>VCUG (only required if recurrent febrile UTI is present)</p>
<p><b>MANAGEMENT</b></p>
<ul style="list-style-type: none"> <li>- If UTI is present, treat UTI first</li> <li>- If constipated, treat bowel first with dietary changes and laxatives</li> <li>- Urotherapy is initial therapy in all cases to maintain controlled fluid intake, regular and efficient bladder emptying</li> <li>- Medical treatment (anticholinergics); if OAB symptoms dominate and persist despite urotherapy</li> <li>- Antibiotic prophylaxis: in case of recurrent UTI</li> <li>- Biofeedback is optional as first line therapy as part of urotherapy program; otherwise it is recommended if refractory to urotherapy</li> <li>- Neural stimulation or Botulinum Toxin A injection in detrusor is suggested if refractory to urotherapy and medical treatment but is still experimental</li> </ul>

<b>Recommendations</b>	<b>Strength rating</b>
Use two day voiding diaries and/or structured questionnaires for objective evaluation of symptoms, voiding drinking habits and response to treatment.	Strong
Use a stepwise approach, starting with the least invasive treatment in managing day-time lower urinary tract dysfunction in children.	Weak

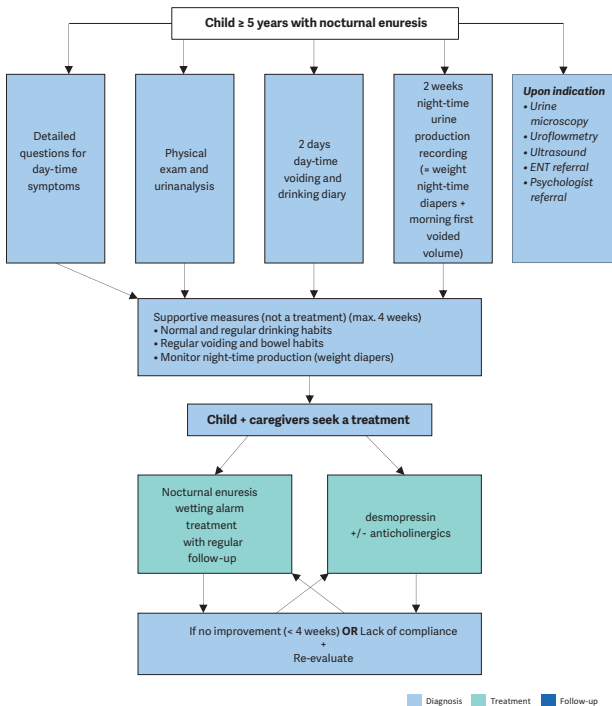
Initially offer urotherapy involving bladder rehabilitation and bowel management.	Weak
If bladder bowel dysfunction is present, treat bowel dysfunction first, before treating the lower urinary tract condition.	Weak
Use pharmacotherapy (mainly antispasmodics and anticholinergics) as second-line therapy in overactive bladder.	Strong
Use antibiotic prophylaxis if there are recurrent infections.	Weak
Re-evaluate in case of treatment failure; this may consist of (video) urodynamics magnetic resonance imaging of lumbosacral spine and other diagnostic modalities, guiding to off-label treatment which should only be offered in highly experienced centres.	Weak

## MONOSYMPOMATIC NOCTURNAL ENURESIS - BEDWETTING

Monosymptomatic nocturnal enuresis is incontinence during the night without daytime symptoms above the age of five years. Due to an imbalance between night-time urine output and night-time bladder capacity, the bladder can easily become full at night, and the child will either wake-up to empty the bladder or will void during sleep.

A voiding diary, registering the day-time bladder function and the night-time urine output will help guide the treatment.

**Figure 9: A stepwise assessment and management options for nocturnal enuresis**



ENT = ear, nose, throat

Recommendations	Strength rating
Do not treat children less than five years of age in whom spontaneous cure is likely, but inform the family about the involuntary nature, the high incidence of spontaneous resolution and the fact that punishment will not help to improve the condition.	Strong
Use micturition diaries or questionnaires to exclude day-time symptoms.	Strong
Perform a urine test to exclude the presence of infection or potential causes such as diabetes insipidus.	Strong
Offer supportive measures in conjunction with other treatment modalities, of which pharmacological and alarm treatment are the two most important.	Strong
Offer desmopressin in proven night-time polyuria.	Strong
Offer alarm treatment in motivated and compliant families.	Strong

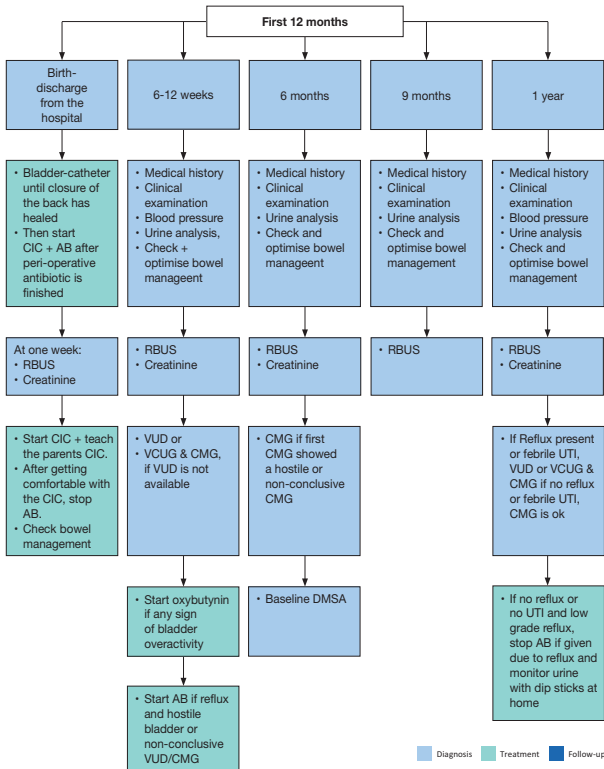
## MANAGEMENT OF NEUROGENIC BLADDER

Neurogenic detrusor-sphincter dysfunction may result in different forms of lower urinary tract dysfunctions and in incontinence, urinary tract infections, vesico-ureteral reflux, renal scarring and renal insufficiency. The most common cause in children is myelodysplasia. Bladder and bowel dysfunction correlates poorly with the type and level of the spinal cord lesion. Therefore, urodynamic and functional classifications are required to define the extent of the pathology and in guiding treatment planning. Children with neurogenic bladder can also have disturbances of bowel and sexual function. The main goals of treatment are prevention of

urinary tract deterioration, achievement of continence at an appropriate age and also improving quality of life.

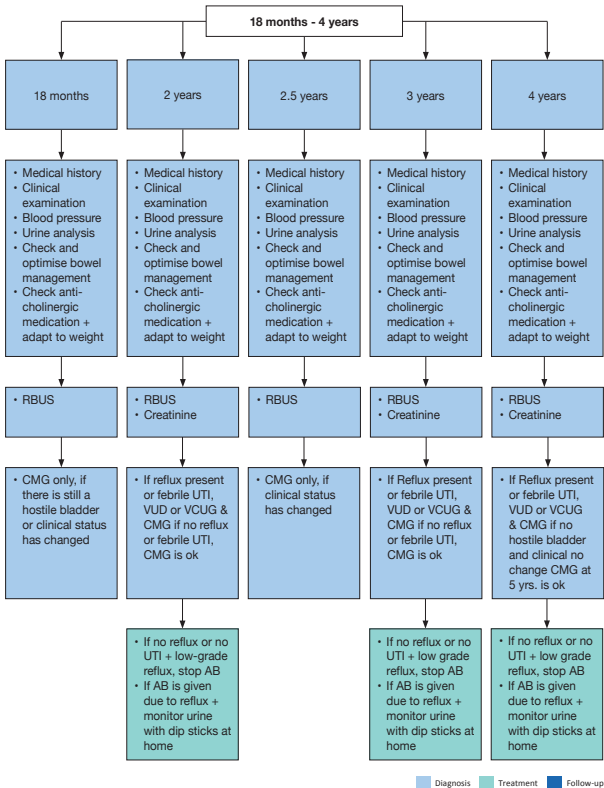
**Figure 10: Management of children with myelodysplasia with a neurogenic bladder Flowchart - First year of life**

**Flowchart - First year of life**



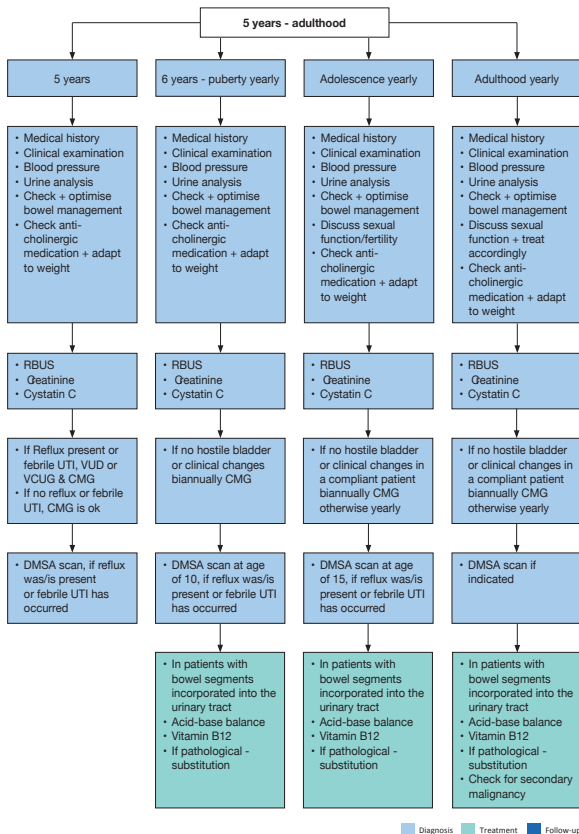


## Flowchart - 18 months – 4 years of age



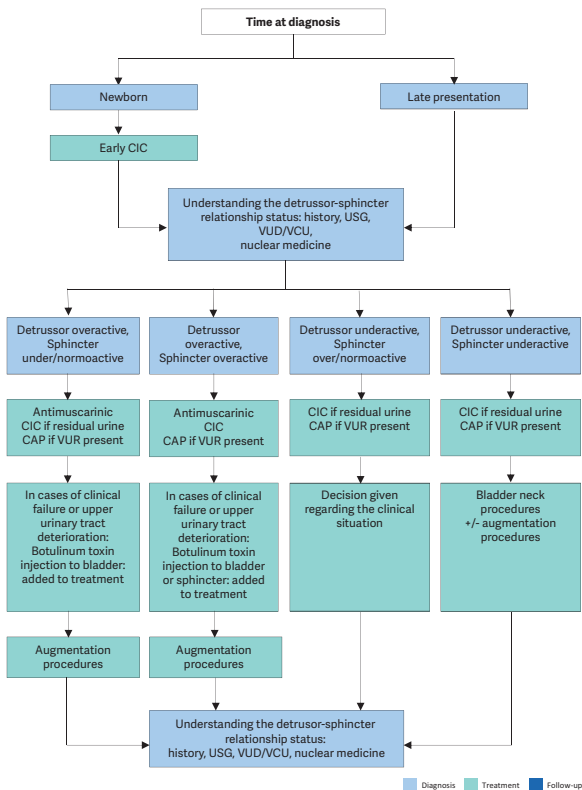
■ Diagnosis   
 ■ Treatment   
 ■ Follow-up

## Flowchart - 5 years to adulthood



*RBUS = Renal bladder ultrasound; UTI = urinary tract infection; VUD = videourodynamic; VCUG = voiding cystourethrography; CMG = cystometrogram; DMSA = dimercaptosuccinic acid.*

**Figure 11: Algorithm for the management of children with myelodysplasia with a neurogenic bladder**



CAP = continuous antibiotic prophylaxis; CIC = clean intermittent catheterisation; US = ultrasound; VCUG = voiding cystourethrography; VUD = videourodynamic; VUR = vesicoureteric reflux.

Recommendations	Strength rating
Urodynamic studies should be performed in every patient with spina bifida as well as in every child with high suspicion of a neurogenic bladder to estimate the risk for the upper urinary tract and to evaluate the function of the detrusor and the sphincter.	Strong
In all newborns, intermittent catheterisation (IC) should be started soon after birth. In those with a clear underactive sphincter and no overactivity, starting IC may be delayed. If IC is delayed, closely monitor babies for urinary tract infections, upper tract changes (US) and the lower tract (UD).	Strong
Start early anticholinergic medication in the newborns with suspicion of an overactive detrusor.	Strong
The use of suburothelial or intradetrusor injection of onabotulinum toxin A is an alternative and a less invasive option in children who are refractory to anticholinergics in contrast to bladder augmentation.	Strong
Treatment of faecal incontinence is important to gain continence and independence. Treatment should be started with mild laxatives, rectal suppositories as well as digital stimulation. If not sufficient transanal irrigation is recommended, if not practicable or feasible, a Malone antegrade colonic enema (MACE)/Antegrade continence enema (ACE) stoma should be discussed.	Strong

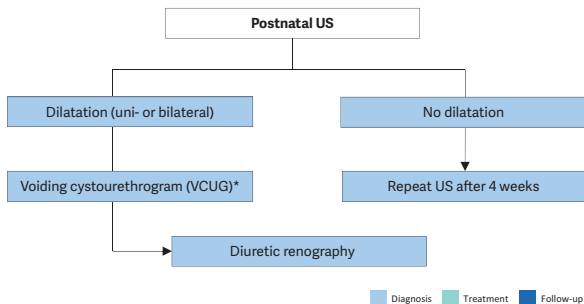
<p>Ileal or colonic bladder augmentation is recommended in patients with therapy resistant overactivity of the detrusor, small capacity and poor compliance, which may cause upper tract damage and incontinence. The risk of surgical and non-surgical complications and consequences outweigh the risk of permanent damage of the upper urinary tract +/- incontinence due to the detrusor.</p>	<p>Strong</p>
<p>In patients with a neurogenic bladder and a weak sphincter, a bladder outlet procedure should be offered. It should be done in most patients together with a bladder augmentation.</p>	<p>Weak</p>
<p>Creation of a continent cutaneous catheterisable channel should be offered to patients who have difficulties in performing an IC through the urethra.</p>	<p>Weak</p>
<p>A life-long follow-up of renal and reservoir function should be available and offered to every patient. Addressing sexuality and fertility starting before/during puberty should be offered.</p>	<p>Weak</p>
<p>Urinary tract infections are common in children with neurogenic bladders, however, only symptomatic UTIs should be treated.</p>	<p>Weak</p>

## DILATATION OF THE UPPER URINARY TRACT (UPJ AND UVJ OBSTRUCTION)

Dilatation of the upper urinary tract remains a significant clinical challenge in deciding which patient will benefit from treatment. Ureteropelvic junction obstruction is the most common pathological cause of neonatal hydronephrosis.

Megaureters (obstruction at the level of the ureterovesical junction) are the second most likely cause of pathological neonatal hydronephrosis. The widespread use of US during pregnancy has resulted in a higher detection rate for antenatal hydronephrosis. The challenge in the management of dilated upper tracts is to decide which child should be observed, which managed medically, and which requires surgical intervention.

**Figure 12: Diagnostic algorithm for dilatation of the upper urinary tract**



\* A diagnostic work-up including VCUG must be discussed with the caregivers, as it is possible that, even if reflux is detected, it may have absolutely no clinical impact. However, it should be borne in mind that reflux has been detected in up to 25% of prenatally detected cases.

US = ultrasound.

Recommendations	Strength rating
Include serial ultrasound (US) and subsequent diuretic renogram and sometimes voiding cystourethrography in post-natal investigations.	Strong
Offer continuous antibiotic prophylaxis to the subgroup of children with antenatal hydronephrosis who are at high risk of developing urinary tract infection like uncircumcised infants, children diagnosed with hydroureteronephrosis and high-grade hydronephrosis, respectively.	Weak
Decide on surgical intervention based on the time course of the hydronephrosis and the impairment of renal function.	Weak
Offer surgical intervention in case of an impaired split renal function due to obstruction or a decrease of split renal function in subsequent studies and increased anteroposterior diameter on the US, and grade IV dilatation as defined by the Society for Fetal Urology.	Weak

Offer pyeloplasty when ureteropelvic junction obstruction has been confirmed clinically or with serial imaging studies proving a substantially impaired or decrease in function.	Weak
Do not offer surgery as a standard for primary megaureters since the spontaneous remission rates are as high as 85%.	Weak

## VESICoureTERIC REFLUX IN CHILDREN

Vesicoureteric reflux (VUR) presents with a wide range of severities, and the majority of reflux patients will not develop renal scars and probably will not need any intervention. The main goal in management is the preservation of kidney function.

The diagnostic work-up should evaluate the overall health and development of the child including a detailed medical history (including family history, and screening for lower urinary tract and/or bowel dysfunction [LUTD]), physical examination together with blood pressure measurement, urinalysis (assessing proteinuria), urine culture, and serum creatinine in patients with bilateral renal parenchymal abnormalities. Voiding cystourethrography still remains the gold standard in diagnosing VUR.

<b>Recommendation for diagnostic evaluation</b>	<b>Strength rating</b>
For diagnosis of VUR apart from VCUG , ceVUS is another option.	Weak

<b>Recommendation for screening</b>	<b>Strength rating</b>
Inform parents of children with vesicoureteric reflux (VUR) that siblings and offspring have a high prevalence of VUR.	Strong



<b>Recommendations for treatment</b>	<b>Strength rating</b>
Initially treat all symptomatic patients diagnosed within the first year of life with continuous antibiotic prophylaxis, regardless of the grade of reflux or presence of renal scars.	Weak
Offer immediate, parenteral antibiotic treatment for febrile breakthrough infections.	Strong
Initially manage all children presenting at age one to five years conservatively.	Strong
Offer close surveillance without antibiotic prophylaxis to children presenting with lower grades of reflux and without symptoms.	Strong
Ensure that a detailed investigation for the presence of lower urinary tract dysfunction (LUTD) is done in all and especially in children after toilet-training. If LUTD is found, the initial treatment should always be for LUTD.	Strong
Offer reimplantation or endoscopic correction to patients with frequent breakthrough infections.	Weak
Offer reimplantation to patients with persistent high-grade reflux and endoscopic correction for lower grades of reflux.	Strong
Offer surgical repair to children above the age of one presenting with high-grade reflux and abnormal renal parenchyma.	Weak
Offer surgical correction, if parents prefer definitive therapy to conservative management.	Strong

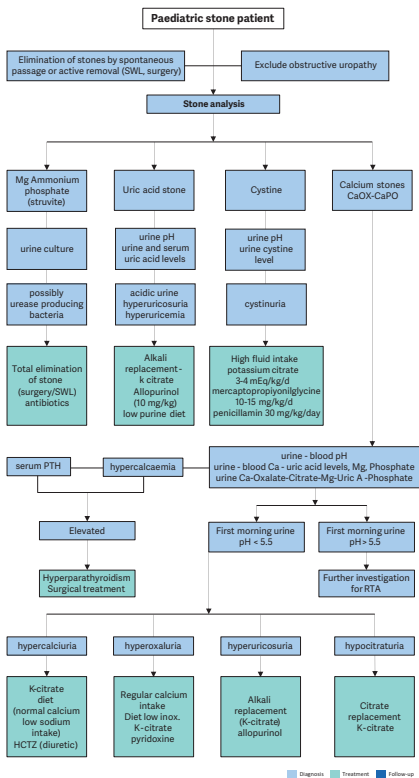
<p>Select the most appropriate management option based on:</p> <ul style="list-style-type: none"> <li>• the presence of renal scars;</li> <li>• clinical course;</li> <li>• the grade of reflux;</li> <li>• ipsilateral renal function;</li> <li>• bilaterality;</li> <li>• bladder/bowel function;</li> <li>• associated anomalies of the urinary tract;</li> <li>• age and gender;</li> <li>• compliance;</li> <li>• parental preference.</li> </ul>	Weak
<p>In high-risk patients who already have renal impairment, a more aggressive, multi-disciplinary approach is needed.</p>	Strong

## URINARY STONE DISEASE

Paediatric stone disease is an important clinical problem in paediatric urology practice. Due to its recurrent nature, every effort should be made to discover the underlying metabolic abnormality so that it can be treated appropriately.

Presentation tends to be age-dependent, with symptoms such as flank pain and haematuria being more common in older children. Infantile urolithiasis appears to be a separate entity since the aetiology and the clinical course is different than in other age groups. Non-specific symptoms (e.g. irritability, vomiting) are common in very young children. Adequate fluid intake and restricting the use of salt within daily allowance range are the general recommendations besides the specific medical treatment against the detected metabolic abnormalities. With the advance of technology, stone management has changed from open surgical approaches to endoscopic techniques that are less invasive.

**Figure 13: Algorithm for metabolic investigations in urinary stone disease in children**



Ca = calcium; HCTZ = hydrochlorothiazide; Mg = magnesium; Ox = oxalate; PTH = parathyroid hormone; SWL = extracorporeal shockwave lithotripsy; RTA = renal tubular acidosis; Uric A = uric acid.

**Table 2: Recommendations for interventional management in paediatric stones**

Stone size and localisation*	Primary treatment option	Secondary treatment options	Comment
Infant micro-lithiasis (<3mm, any location)	Observation	Intervention and/or medical treatment	Individualised decision according to size progression, symptoms and metabolic factors.
Staghorn stones	PCNL	Open/SWL	Multiple sessions and accesses with PCNL may be needed. Combination with SWL may be useful.
Pelvis < 10 mm	SWL	RIRS/PCNL	
Pelvis 10-20 mm	SWL/PCNL/RIRS		Multiple sessions with SWL may be needed. PCNL and RIRS have a similar recommendation grade.
Pelvis > 20 mm	PCNL	SWL/RIRS	Multiple sessions with SWL may be needed.
Lower pole calyx < 10mm	Observation or SWL	PCNL/RIRS	Stone clearance after SWL is lower than other locations.

Lower pole calyx > 10mm	PCNL	RIRS/SWL	Anatomical variations are important for complete clearance after SWL.
Upper ureteric stones	SWL	URS	Flexible scopes may be needed in case of retropulsion.
Lower ureteric stones	URS	SWL	
Bladder stones	Endoscopic (transurethral or percutaneous)	SWL/Open	Open is easier and with less operative time with large stones.

\* Cystine and uric acid stones excluded.

PCNL = percutaneous nephrolithotomy; SWL = shockwave lithotripsy; RIRS = retrograde intrarenal surgery; URS = ureteroscopy.

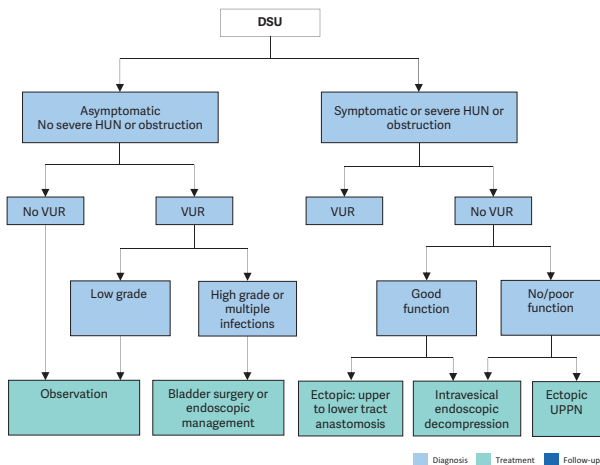
Recommendations	Strength rating
Use plain abdominal X-ray and ultrasound as the primary imaging techniques for the diagnosis and follow-up of stones.	Strong
Use low-dose non-contrast computed tomography in cases with a doubtful diagnosis, especially of ureteral stones or complex cases requiring surgery.	Strong

Perform a metabolic evaluation in any child with urinary stone disease. Any kind of interventional treatment should be supported with medical treatment for the underlying metabolic abnormality, if detected.	Strong
Limit open surgery under circumstances in which the child is very young with large stones, in association with congenital problems requiring surgical correction and/or with severe orthopaedic deformities that limit positioning for endoscopic procedures.	Strong
Observe infant microlithiasis, unless symptoms occur or size increases significantly.	Strong

## **OBSTRUCTIVE PATHOLOGY OF RENAL DUPLICATION: URETEROCELE AND ECTOPIC URETER**

Ureterocele and ectopic ureter are the two main anomalies associated with complete renal duplication. Antenatal US detects both conditions in the majority of cases if associated with obstruction, and diagnosis is confirmed after birth. Later in life, these anomalies are revealed by clinical symptoms: UTI, pain, calculus formation, disturbances of micturition, and urinary incontinence. There is a wide variation of symptoms in patients with ureterocele (from the asymptomatic patient to urosepsis, urinary retention and upper tract dilatation after birth). Ectopic ureter is less frequent than ureterocele and more common in females with some remaining asymptomatic.

**Figure 14: Algorithm for the management of duplex system ureterocele after the first 3-6 months of life**



*DSU = duplex system ureterocele; HUN = hydroureteronephrosis; UPPN = upper pole partial nephrectomy; VUR = vesicoureteric reflux to the lower pole.*

<b>Recommendations</b>		<b>Strength rating</b>
<b>Ureterocele</b>		
Diagnosis	Use ultrasound (US), radionuclide studies (mercaptoacetyltriglycine (MAG3)/ dimercaptosuccinic acid (DMSA)), voiding cystourethrography (VCUG), magnetic resonance urography, high-resolution magnetic resonance imaging (MRI), and cystoscopy to assess function, to detect reflux and rule out ipsilateral compression of the lower pole and urethral obstruction.	Weak
Treatment	Select treatment based on symptoms, function and reflux as well on surgical and parenteral choices: observation, Endoscopic decompression, ureteral re-implantation, partial nephroureterectomy, complete primary reconstruction. Offer early endoscopic decompression to patients with an obstructing ureterocele.	Weak
<b>Ectopic ureter</b>		
Diagnosis	Use US, DMSA scan, VCUG or MRI for a definitive diagnosis.	Weak



Treatment	In non-functioning moieties with recurrent infections, heminephro-ureterectomy is a definitive solution. Ureteral reconstruction (ureteral re-implantation/ureteroureterostomy/ureteropyelostomy and upper-pole ureterectomy) are other therapeutic option especially in cases in which the upper pole has function worth preserving.	Weak
-----------	---	------

## DISORDERS/DIFFERENCES OF SEX DEVELOPMENT

The term 'disorders of sex development' is proposed to indicate congenital conditions with atypical development of chromosomal, gonadal or anatomical sex. Dealing with neonates with DSD requires a multi-disciplinary approach, which should include geneticists, neonatologists, paediatric and adult endocrinologists, gynaecologists, psychologists, ethicists and social workers with each team member specialised in DSD.

**Table 3: Findings in a newborn suggesting the possibility of DSD** (adapted from the American Academy of Pediatrics)

<b>Apparent male</b>
Severe hypospadias associated with bifid scrotum
Undescended testis/testes with hypospadias
Bilateral non-palpable testes in a full-term apparently male infant
<b>Apparent female</b>
Clitoral hypertrophy of any degree, non-palpable gonads
Vulva with single opening
Indeterminate
Ambiguous genitalia

**Table 4: Diagnostic work-up of neonates with disorders of sex development**

<b>History (family, maternal, neonatal)</b>
Parental consanguinity
Previous DSD or genital anomalies
Previous neonatal deaths
Primary amenorrhoea or infertility in other family members
Maternal exposure to androgens
Failure to thrive, vomiting, diarrhoea of the neonate
<b>Physical examination</b>
Pigmentation of genital and areolar area
Hypospadias or urogenital sinus
Size of phallus
Palpable and/or symmetrical gonads
Blood pressure
<b>Investigations</b>
Blood analysis: 17-hydroxyprogesterone, electrolytes, LH, FSH, TST, cortisol, ACTH
Urine: adrenal steroids
Genetics: karyotype, next-generation sequencing-based molecular diagnostics, WES
Ultrasound
Genitogram
hCG stimulation test to confirm presence of testicular tissue
Androgen-binding studies
Endoscopy

*ACTH = adrenocorticotrophic hormone; FSH = follicle-stimulating hormone; hCG = human chorionic gonadotropin; LH = luteinising hormone; TST = testosterone.*

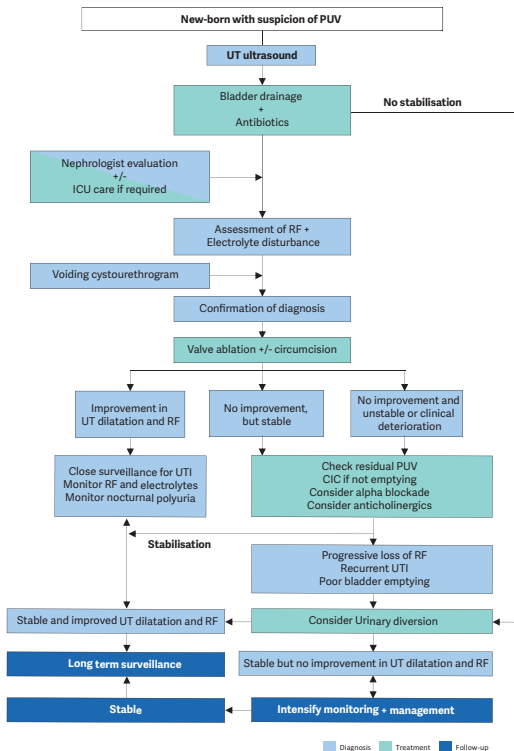
Recommendations	Strength rating
Do not delay diagnosis and treatment of any neonate presenting with ambiguous genitalia since salt-loss in a 46XX CAH girl can be fatal.	Strong
Refer children to experienced centres where neonatology, endocrinology, (paediatric) urology, psychology and transition to adult care are guaranteed.	Strong
Utilise a multi-disciplinary approach and a shared decision model in patients with DSD conditions including: <ol style="list-style-type: none"> <li>Gender assignment</li> <li>Genital surgery (in accordance with national regulations)</li> <li>Gonadectomy.</li> </ol>	Strong
Do not underestimate the significant effects on psychological and psychiatric health, quality of life, personal relationships, and sexual function in individuals with DSD.	Strong
Ensure full disclosure to patients and caregivers that the presence of a Y-chromosome in dysgenetic gonads results in a higher malignancy risk	Strong

## CONGENITAL LOWER URINARY TRACT OBSTRUCTION (CLUTO)

The term CLUTO is used for a foetus, which during intrauterine US screening shows a dilatation of the upper and lower urinary tract. During pregnancy the diagnosis is usually based on ultrasound examinations only. There is a broad spectrum of conditions that could cause an intra-uterine dilation of the urinary tract. Postpartum diagnosis

comprises any number of anatomical and functional disorders/anomalies/malformations causing dilatation e.g. anterior urethral valves, urethral atresia/ stenosis, prune belly syndrome, dilating VUR , cloacal malformation, prolapsing ureterocele, megacystis-microcolon-intestinal hypoperistalsis or megacystis-megaureter syndrome.

**Figure 15: An algorithm on the assessment, management and follow-up of new-borns with possible PUV**



*CIC = clean intermittent catheterisation; OAB = overactive bladder; PUV = posterior urethral valve; RF = renal function; UT = urinary tract; UUT = upper urinary tract; VCUG = voiding cystourethrogram.*

<b>Recommendations</b>	<b>Strength rating</b>
Drain the bladder in new-borns with a suspected diagnosis of infravesical obstruction and place on antibiotic prophylaxis.	Strong
Perform a voiding cystourethrogram (VCUG) in patients in whom a diagnosis of posterior urethral valve (PUV) is suspected.	Strong
Attempt endoscopic valve ablation after bladder drainage and stabilisation of the child.	Strong
Consider neonatal circumcision as an adjunct to antibiotic prophylaxis to decrease the risk of UTI in those with a PUV, especially in the presence of high grade vesicoureteral reflux.	Strong
Offer prolonged urinary diversion (suprapubic/transurethral) for bladder drainage if the child is too small for valve ablation.	Strong
Use serum creatinine nadir as a prognostic marker.	Strong
Assess split renal function by dimercaptosuccinic acid (DMSA) scan or mercaptoacetyltriglycine (MAG3) clearance.	Strong
Consider high urinary diversion if bladder drainage is insufficient to drain the upper urinary tract, or in the absence of clinico-biochemical improvement.	Strong
Monitor and manage bladder and renal function lifelong.	Strong

## RARE CONDITIONS:

### Urachal remnants

Urachal remnants originate from failure of the obliteration of the allantois, resulting in a urachal anomaly such as urachal sinus, urachal cyst, vesico-urachal diverticulum, and patent urachus, respectively. Most often the urachal anomaly is asymptomatic, but it occasionally may become infected, may cause urinary symptoms, or may develop a urachal carcinoma in later life.

Recommendations	Strength rating
Urachal remnants with no epithelial tissue carry little risk of malignant transformation.	Strong
Asymptomatic and non-specific atretic urachal remnants can safely be managed non-operatively.	Strong
Urachal remnants incidentally identified during diagnostic imaging for non-specific symptoms should also be observed non-operatively since they tend to resolve spontaneously.	Strong
A small urachal remnant, especially at birth, may be viewed as physiological.	Strong
Urachal remnants in patients younger than six months are likely to resolve with non-operative management.	Strong
Follow-up is necessary only when symptomatic for six to twelve months.	Strong
Surgical excision of urachal remnants solely as a preventive measure against later malignancy appears to have minimal support in the literature.	Strong

Only symptomatic urachal remnants should be safely removed by open or laparoscopic approach.	Strong
A voiding cystourethrogram is only recommended when presenting with febrile urinary tract infections.	Strong

## Papillary tumours of the bladder

Papillary tumours of the bladder in children and adolescents are extremely rare and are different from papillary tumours in adults.

Recommendations	Strength rating
Ultrasound is the first investigation of choice for the diagnosis of paediatric bladder tumours.	Strong
Cystoscopy should be reserved if a bladder tumour is suspected on imaging for diagnosis and treatment.	Strong
After histological confirmation, inflammatory myofibroblastic bladder tumours should be resected locally.	Weak
Follow-up should be every 3-6 months in the first year, and thereafter at least annually with urinalysis and an ultrasound for at least 5 years.	Weak
Have a high index of suspicion of eosinophilic cystitis (EC) in protracted urinary tract symptoms unresponsive to regular treatment.	Strong
Remove any possible allergens as the obvious first step in managing EC.	Strong



Eosinophilic cystitis can be managed medically with corticosteroids, antibiotics, anticholinergics, and antihistamines, in addition to cyclosporine A.	Weak
Manage nephrogenic adenoma (NA) by resection either transurethraly or by open excision.	Strong
Regular endoscopic follow-up especially for augmented patients with NA is justified.	Weak

## Penile lesions

Paediatric lesions of the penis are uncommon but an important part of the paediatric urological practice. The most common of these lesions are cystic penile lesions followed by vascular malformations and neurogenic lesions. Soft tissue tumours of the male external genitalia are uncommon, but have been described in the paediatric age group and can be malignant.

Recommendations	Strength rating
Treatment of penile cystic lesions is by total surgical excision, it is mainly indicated for cosmetic or symptomatic (e.g. infection) reasons.	Weak
Propranolol is currently first-line treatment for infantile haemangiomas.	Strong

## Penile lymphedema

Paediatric lymphedema is usually primary and generally very rare. Inefficient lymphatic drainage leads to accumulation of subcutaneous lymph causing tissue swelling and inflammation and subsequently stimulates adipose deposition and fibrosis further exacerbating enlargement. With time the edematous

tissue becomes vulnerable to infection, chronic cutaneous changes and disfigurement. Complications may ensue such as phimosis, haematuria, bleeding, bladder outlet obstruction, pain, dysuria, lymphorrhoea and severe psychological distress due to resultant deformity.

Recommendations	Strength rating
Conservative management is the first-line treatment for penile lymphedema.	Strong
In symptomatic cases or in patients with functional impairment, surgical intervention may become necessary for penile lymphedema.	Weak

## PAEDIATRIC UROLOGICAL TRAUMA/EMERGENCIES

In about 3% of children seen at paediatric hospital trauma centres, there is significant involvement of the genitourinary tract. This is caused by either blunt injuries from falls, car accidents, sports injuries, physical assault, and sexual abuse, or penetrating injuries, usually due to falls onto sharp objects or from gunshot or knife wounds.

### Paediatric renal trauma

**Table 5: Renal injury classified according to the kidney injury scale of the American Association for the Surgery of Trauma**

Grade	Type of injury	Description
I	Haematoma and/or contusion	Subcapsular haematoma and/or parenchymal contusion without laceration

II	Haematoma	Perirenal haematoma confined to Gerota fascia
	Laceration	Renal parenchymal laceration $\leq 1$ cm depth without urinary extravasation
III	Laceration	Renal parenchymal laceration $> 1$ cm depth without collecting system rupture or urinary extravasation
	Vascular	Any injury in the presence of a kidney vascular injury or active bleeding contained within Gerota fascia
IV	Laceration	<ul style="list-style-type: none"> <li>- Parenchymal laceration extending into urinary collecting system with urinary extravasation</li> <li>- Renal pelvis laceration and/or complete ureteropelvic disruption</li> </ul>
	Vascular	<ul style="list-style-type: none"> <li>- Segmental renal vein or artery injury</li> <li>- Active bleeding beyond Gerota fascia into the retroperitoneum or peritoneum</li> <li>- Segmental or complete kidney infarction(s) due to vessel thrombosis without active bleeding</li> </ul>
V	Laceration	Shattered kidney with loss of identifiable parenchymal renal anatomy
	Vascular	<ul style="list-style-type: none"> <li>- Main renal artery or vein laceration or avulsion of hilum</li> <li>- Devascularized kidney with active bleeding</li> </ul>

Vascular injury is defined as a pseudoaneurysm or arteriovenous fistula and appears as a focal collection of vascular contrast that decreases in attenuation with delayed imaging. Active bleeding from a vascular injury presents as vascular contrast, focal or diffuse, that increases in size or attenuation in delayed phase. Vascular thrombosis can lead to organ infarction. Grade based on highest grade assessment made on imaging, at operation or on pathologic specimen. More than one grade of kidney injury may be present and should be classified by the higher grade of injury. Advance one grade for bilateral injuries up to Grade III.

<b>Recommendations</b>	<b>Strength rating</b>
Use imaging in all children who have sustained a blunt or penetrating trauma with any level of haematuria, especially when the history reveals a deceleration trauma, direct flank trauma or a fall from a height.	Strong
Use contrast enhanced CT-scanning with delayed images for diagnostic and staging purposes.	Strong
Manage most injured kidneys conservatively.	Strong
Offer surgical intervention in case of haemodynamic instability and a Grade V renal injury.	Strong

### **Paediatric ureteral trauma**

<b>Recommendations</b>	<b>Strength rating</b>
Diagnose suspected ureteral injuries by retrograde pyelogram.	Strong

Manage ureteral injuries endoscopically, using internal stenting or drainage of an urinoma, either percutaneously or via a nephrostomy tube.	Weak
--	------

### **Paediatric bladder injuries**

<b>Recommendations</b>	<b>Strength rating</b>
Use retrograde cystography to diagnose suspected bladder injuries.	Strong
Ensure that the bladder has been filled to its full capacity and an additional film is taken after drainage.	Strong
Manage extra-peritoneal bladder ruptures conservatively with a transurethral catheter left in place for seven to ten days.	Strong
Perform surgical exploration in cases of intra-peritoneal bladder ruptures.	Strong

### **Paediatric urethral injuries**

<b>Recommendations</b>	<b>Strength rating</b>
Assess the urethra by retrograde urethrogram in case of suspected urethral trauma.	Strong
Perform a rectal examination to determine the position of the prostate.	Strong
Manage urethral injuries conservatively initially if a transurethral catheter can be placed.	Strong

Manage posterior urethral injuries by either: <ul style="list-style-type: none"> <li>• primary drainage with a suprapubic catheter alone and delayed repair</li> <li>• primary re-alignment with a transurethral catheter</li> </ul>	Weak
--	------

## Priapism

Priapism is a prolonged full or partial erection of the penis unrelated to sexual stimuli lasting  $\geq 4$  hours. Although the prevalence of priapism in children is not well reported in literature, it is considered a rare disease. The most common cause of priapism in children is sickle cell disease (SCD), which accounts for about 65% of all cases, followed by leukemia (10%), trauma (10%), idiopathic (10%) and drugs (5%). In patients with SCD, the mean age of the first episode of priapism has been shown to be 15 years old, with 25% presenting prepubertally.

Recommendations	Strength rating
Perform a doppler ultrasonography in all patients presenting with priapism.	Strong
In children with ischaemic (low-flow) priapism, perform a full blood count and haemoglobinopathy screen to exclude sickle cell disease or other haematological disorders.	Strong
Adopt a multidisciplinary approach when managing patients with SCD-associated priapism.	Strong
Use a step-wise approach starting with the least invasive therapy in patients with ischaemic (low-flow) priapism.	Strong

Manage neonatal and non-ischaemic (high-flow) priapism conservatively in the initial management period.	Strong
---	--------

## PERI-OPERATIVE FLUID MANAGEMENT

Children have a different total body fluid distribution, renal physiology and electrolyte requirements, as well as weaker cardiovascular compensation mechanisms, compared to adults. Therefore, special child specific requirements regarding preoperative fasting and intra- as well as post-operative fluid have to be considered and close monitoring is essential. This is especially true for interventions relieving any kind of obstruction as this may result in substantial polyuria.

**Table 6: Pre-operative fasting times for elective surgery**

Ingested material	Minimum fasting period (hours)
Clear liquids	1
Breast milk	3
Formula milk-based products	4
Light meal	6

Recommendations	Strength rating
Ensure shorter pre-operative fasting periods for elective surgeries (one hour for clear liquids, three hours for breast milk, four hours for formula milk-based products and six hours for a light meal).	Strong
Start early postoperative oral fluid intake in all patients scheduled for minor surgical procedures.	Strong

Use enhanced recovery after surgery protocols for abdominal surgery in children with pre-existing normal bowel function.	Strong
--	--------

## POST-OPERATIVE PAIN MANAGEMENT

The provision of adequate pain control requires proper pain evaluation, accurate choice of drug and route of administration, and consideration of age, physical condition and type of surgery and anaesthesia.

A proposed strategy for post-operative analgesia may be as follows:

1. Intra-operative regional block and/or local wound infiltration.
2. Paracetamol + NSAID.
3. Paracetamol + NSAID + weak opioid (e.g. tramadol or codeine).
4. Paracetamol + NSAID + strong opioid (e.g. morphine, fentanyl, oxycodone or pethidine).

Recommendations	Strength rating
Prevent/treat pain in children of all ages.	Strong
Evaluate pain using age-compatible assessment tools.	Strong
Use pre-emptive and balanced analgesia in order to decrease opioids requirements.	Strong

## Thromboprophylaxis management: general information

Thromboprophylaxis in children involves preventive measures aimed at reducing the risk of blood clot formation. Unlike adults, the majority of children do not require thromboprophylaxis after surgery. It is only considered in certain high-risk situations such as underlying medical conditions like malignancies, congenital heart disease etc.



Recommendations	Strength rating
Use physical methods for venous thromboembolism (VTE) risk reduction in older children and adolescents who are at increased risk of VTE.	Strong
Consider low molecular weight heparin VTE prophylaxis in children, particularly adolescents, with additional risk factors.	Strong

### Premedication management: general information

The majority of children undergoing anaesthesia and surgery develop anxiety that could lead to adverse reactions. Many factors may influence preoperative anxiety. Anxiety and distress can be prevented or relieved combining: premedication, distraction techniques and parental or caregivers presence. Non-pharmacological age-appropriate methods such as play therapy, toys, storybooks, videos, tablet, mobile phone, can all be useful. A successful plan must therefore take into account the age and temperament of the child.

Recommendations	Strength rating
Use non-pharmacological age-appropriate premedication methods to decrease anxiety levels in children before surgery.	Weak
Use pharmacological premedication to decrease anxiety levels in children and monitor for potential side effects.	Strong

## BASIC PRINCIPLES OF LAPAROSCOPIC SURGERY IN CHILDREN

Laparoscopy in children requires specific anaesthetic precautions. Physiological effects of CO<sub>2</sub> pneumoperitoneum, positioning of the patient and operative time need to be considered by the anaesthesiology team.

Recommendations	Strength rating
Use lower intra-abdominal pressure (6-8 mmHg) during laparoscopic surgery in infants and smaller children.	Strong
Use open access for laparoscopy in infants and smaller children.	Strong
Monitor for laparoscopy-related cardiac, pulmonary and diuretic responses.	Strong

*This short booklet text is based on the more comprehensive EAU Paediatric Urology Guidelines (978-94-92671-23-3), available at their website, <http://www.uroweb.org/guidelines>.*